

## Original Article

# A Comparative Study Analyzing the Size of Mental Foramen in Male, Female, and Transgender Using Cone-Beam Computed Tomography

Poorvi Yadav, Nyamati B Sanjay, Shweta Hegde, Salona Kalra

Department of Oral Medicine and Radiology, Triveni Institute of Dental Sciences Hospital and Research Center, Bilaspur, India

Received: 22 March, 2021.

Revised: 21 April, 2021.

Accepted: 30 April, 2021.

Published: 30 June, 2021.

## BACKGROUND

Human identification is the most difficult task after any natural or man made disaster. Identification of the deceased is important for both legal and humanitarian reasons. Personal identification is highly relevant in forensic science.<sup>[1]</sup> The forensic literature has emphasized on two genders male and female. The existence of a third gender (transgender) is almost negligible in the literature, and this makes it compulsive to determine their identity through forensic approaches at the time of disasters and any other eventualities. To live a dignified life, some of the transgenders undergo feminine facial recontouring surgeries. However, soft tissues of the deceased get decomposed over the time while mandible being the strongest bone of the human body remains in a well-preserved state for long time. Therefore, the morphological feature of the mandible is extensively used by the anthropologist and forensic odontologist for gender estimation. It is the most stable landmark among all skull bone.<sup>[2]</sup> Mental foramen (MF) is a funnel-like opening which is located 11–15 mm superior to the inferior border of mandible.<sup>[3]</sup> Gender identification can be done by the radiographic analysis of the MF, as location

## ABSTRACT

**Background:** Mental foramen (MF) is the anatomical landmark which is oval in shape and present in mandible and shows sexual dimorphism by variation in size and position. The aim of this study was to analyze the size of MF in male, female, and transgender using cone-beam computed tomography (CBCT) and also emphasize on specifically conducting such study on transgenders.

**Materials and Methods:** Axial, coronal, tangential sections of 150 participants (50 males, 50 females, and 50 transgenders) and CBCT mandibular scans aged 25–50 years were prospectively evaluated to determine the size of MF. Differentiating characteristics of genders were evaluated.

**Results:** Transgenders had significantly greater axial and tangential width measurements than males and females. Transgenders had significantly greater coronal height and tangential height measurements than males and females. Mean width of MF  $5.91 \pm 0.14$  (axial),  $6.23 \pm 0.19$  (tangential), mean height of MF  $6.83 \pm 0.31$  (coronal), and  $6.74 \pm 0.32$  (tangential) were observed.

**Conclusion:** It could be concluded that gender identification by MF can be more reliable as it is a stable landmark and shows sexual dimorphism. The present study observed the significant difference in size of the MF in male, female, and transgender.

**KEY WORDS:** Axial width, cone-beam computed tomography, coronal height, mental foramen, tangential height, tangential width

and size of the MF show the sexual dimorphism.<sup>[4]</sup> Using newer imaging modalities such as cone-beam computed tomography (CBCT) in forensic odontology provide most accurate age as well as gender determination.<sup>[5]</sup> This study is focused on the third gender identification by analyzing the size of MF by CBCT.

## MATERIALS AND METHODS

### STUDY COHORT

200 participants were examined those visited in department of oral medicine and radiology, out of which 150 participants (50 males, 50 females, 50 transgenders) were selected for the study based on inclusion criteria. After getting consent from the patients and clearance from the ethical committee of institution, scan of mandible was taken by NEWTOM GiANO 3D CBCT machine and measurement was done by NNT software developed by NEWTOM GiANO, Verona, Italy.

**Address for correspondence:** Dr. Poorvi Yadav,  
E-mail: [drpoorvi178@gmail.com](mailto:drpoorvi178@gmail.com)

This is an open access journal, and articles are distributed under the terms of the Creative Commons Attribution-NonCommercial-ShareAlike 4.0 License, which allows others to remix, tweak, and build upon the work non-commercially, as long as appropriate credit is given and the new creations are licensed under the identical terms.

**For reprints contact:** [WKHLRPMedknow\\_reprints@wolterskluwer.com](mailto:WKHLRPMedknow_reprints@wolterskluwer.com)

**How to cite this article:** Yadav P, Sanjay NB, Hegde S, Kalra S. A comparative study analyzing the size of mental foramen in male, female, and transgender using cone-beam computed tomography. *Int J Forensic Odontol* 2021;6:38-42.

### Access this article online

#### Quick Response Code:



Website: [www.ijfo.org](http://www.ijfo.org)

DOI: 10.4103/ijfo.ijfo\_7\_21

## RECRUITMENT CRITERIA

### Inclusion criteria

Patients who age groups from 25 to 50 years were included in the study. Radiographic images of the MF and the borders of the mandible should be distinct, free of artifacts in the site of measurement.

### Exclusion criteria

Patients with preexisting systemic disorders likely to affect bone metabolism were excluded from the study. Any pathology in the mandible could affect the interpretation of the radiographic image. Patient with malocclusion compounded by severe crowding or spacing in lower arch were excluded from the study. Patients with any bone pathology or alveolar ridge resorption were excluded from the study.

## RADIOGRAPHIC MEASUREMENTS

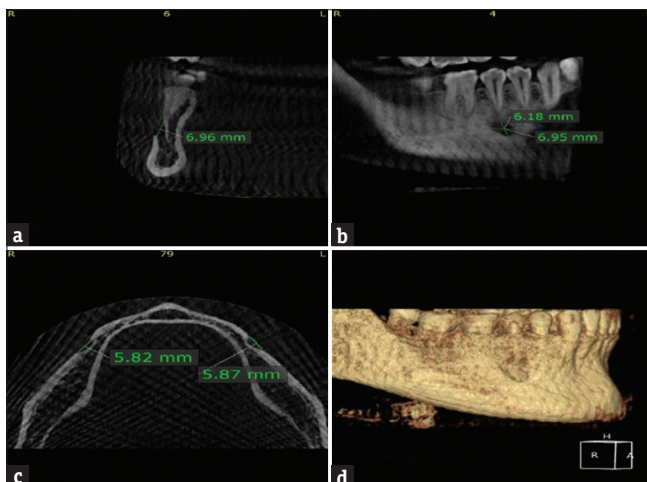
In the axial view a curved line was drawn along the external border of mandible at the level where the greatest extent of the MF was visible. This curve served as a reproducible landmark to reference for measurements across all scanned volumes. It also determined the corrected tangential plane and corrected coronal plane (90° to the corrected plane). In the coronal view, the maximum height (CoronalH) of the MF was measured [Figure 1a]. In the tangential view, the maximum height (TangentialH) and width (TangentialW) of the MF was measured [Figure 1b]. In the axial view, the maximum width (AxialW) of the MF was measured [Figure 1c].

## STATISTICAL ANALYSIS

SPSS v. 20 software was used for statistical analysis (Software developed by Norman H.Nie, Dale H. Bent, C. Hadlai Hull and owned by IBM corporation Armonk, New York, United States). One-way analysis of variance (ANOVA) was done for the comparison between the groups. Tukey's *post hoc* analysis was done for pairwise comparison among the groups. The  $P \leq 0.05$  was considered as statistically significant.

## RESULTS

Scans of 150 participants age between 25 and 50 years were



**Figure 1:** (a) Height of mental foramen in coronal view, (b) height and width of mental foramen in tangential view, (c) width of axial width (d) three-dimensional view mandible

prospectively analyzed of which 50 were males, 50 females, and 50 transgenders. The transgenders showed highest axial width ( $5.91 \pm 0.14$ ) followed by males ( $4.38 \pm 0.41$ ) and females ( $3.07 \pm 0.56$ ), and the difference in axial width between them is statistically significant ( $P < 0.05$ ). Table 1 and Graph 1 show the comparison of mean axial width between the genders. Pairwise comparison of axial width was done among the genders where the mean differences in axial width between males and females, males and transgenders, and females and transgenders are statistically significant ( $P < 0.05$ ). Pairwise comparison of axial width among genders shows in Table 2. The transgenders showed highest coronal height ( $6.83 \pm 0.31$ ) followed by males ( $4.25 \pm 0.26$ ) and females ( $3.15 \pm 0.50$ ), and the difference in coronal height between them was statistically significant ( $P < 0.05$ ). Table 3 and Graph 2 show the comparison of mean coronal height between the genders. Pairwise comparison of coronal height was done among the genders where the mean differences in coronal height between males and females, males and transgenders, and females and transgenders are statistically significant ( $P < 0.05$ ). Pairwise comparison of coronal height shows in Table 4. The transgenders showed highest tangential height ( $6.74 \pm 0.32$ ) followed by males ( $4.09 \pm 0.28$ ) and females ( $3.05 \pm 0.48$ ),

**Table 1: Comparison of axial width between the genders using one-way ANOVA**

Genders	Mean±SD	F	P	Significance (P)
Male	4.38±0.41	585.056	0.000	<0.05
Female	3.07±0.56			
Transgender	5.91±0.14			

SD: Standard deviation

**Table 2: Pairwise comparison of axial width among the genders using Tukey's post hoc analysis**

Pairs	Mean difference	P	Significance (P)
Male versus female	1.31	0.000	<0.05
Male versus transgender	1.53	0.000	
Female versus transgender	2.84	0.000	

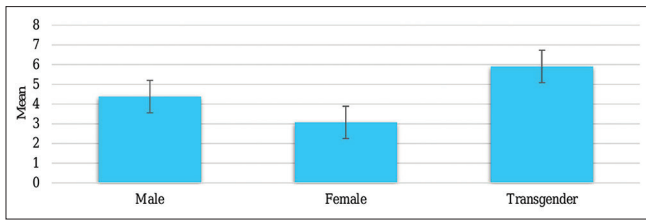
**Table 3: Comparison of coronal height between the genders using one-way ANOVA**

Genders	Mean±SD	F	P	Significance (P)
Male	4.25±0.26	1279.205	0.000	<0.05
Female	3.15±0.50			
Transgender	6.83±0.31			

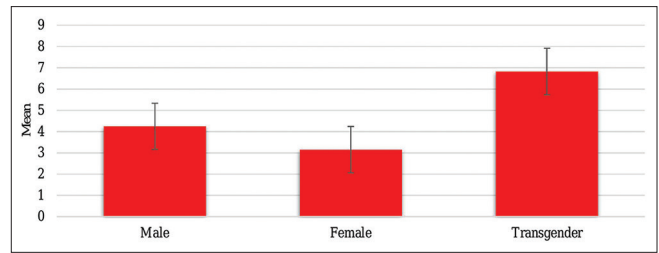
SD: Standard deviation

**Table 4: Pairwise comparison of coronal height among the genders using Tukey's post hoc analysis**

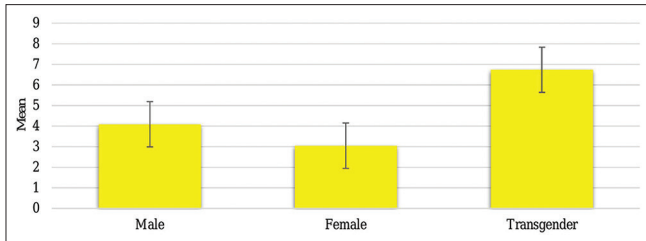
Pairs	Mean difference	P	Significance (P)
Male versus female	1.10	0.000	<0.05
Male versus transgender	2.58	0.000	
Female versus transgender	3.68	0.000	



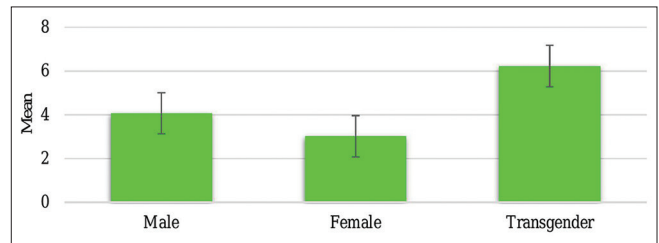
Graph 1: Comparison of axial width between genders



Graph 2: Comparison of coronal height between the genders



Graph 3: Comparison of tangential height between the genders



Graph 4: Comparison of tangential width between the genders

and the difference in tangential height between them is statistically significant ( $P < 0.05$ ). Table 5 and Graph 3 show the comparison of mean tangential height between the genders. Pairwise comparison of tangential height was done among the genders where the mean differences in tangential height between males and females, males and transgenders, and females and transgenders are statistically significant ( $P < 0.05$ ). Pairwise comparison of tangential height among genders shows in Table 6. The transgenders showed highest tangential width ( $6.23 \pm 0.19$ ) followed by males ( $4.07 \pm 0.29$ ) and females ( $3.02 \pm 0.45$ ), and the difference in tangential width between them is statistically significant ( $P < 0.05$ ). Table 7 and Graph 4 show the comparison of mean tangential width between the genders. Pairwise comparison of tangential width was done among the genders where the mean differences in tangential width between males and females, males and transgenders, and females and transgenders are statistically significant ( $P < 0.05$ ). Table 8 shows pairwise comparison of tangential width among genders.

## DISCUSSION

MF provides housing to the mental nerve and vessels. MF appears radiolucent in radiograph which can be misdiagnosed with radiolucent pathology present in the region of MF.<sup>[6]</sup> As MF preserves the mental nerve and vessels, determination of the morphology and position of the MF play important role while performing any surgeries.<sup>[7]</sup>

The position of the MF varies among races, genders, and age.<sup>[7,8]</sup> In infancy, the MF is located low and relatively far posteriorly, below the first molar tooth bud. With the eruption of permanent teeth, the MF moves anteriorly and corresponds to the level of the second premolar tooth.<sup>[9]</sup> Further, variations in the MF ranged from difference in the shape and size. The shape and size of the mandible undergo definitive variations from birth to the old age Figure 1d (3D reconstruction) represents mental foramen.<sup>[10,11]</sup> The aim of present study was to evaluate the size of MF in male, female, and transgenders using cone-beam tomography. Transgenders

Table 5: Comparison of tangential height between the genders using one-way ANOVA

Genders	Mean±SD	F	P	Significance (P)
Male	4.09±0.28	1264.896	0.000	<0.05
Female	3.05±0.48			
Transgender	6.74±0.32			

SD: Standard deviation

Table 6: Pairwise comparison of tangential height among the genders using Tukey's post hoc analysis

Pairs	Mean difference	P	Significance (P)
Male versus female	1.04	0.000	<0.05
Male versus transgender	2.65	0.000	
Female versus transgender	3.69	0.000	

Table 7: Comparison of tangential width between the genders using one-way ANOVA

Genders	Mean±SD	F	P	Significance (P)
Male	4.07±0.29	1223.701	0.000	<0.05
Female	3.02±0.45			
Transgender	6.23±0.19			

SD: Standard deviation

Table 8: Pairwise comparison of tangential width among the genders using Tukey's post hoc analysis

Pairs	Mean difference	P	Significance (P)
Male versus female	1.05	0.000	<0.05
Male versus transgender	2.16	0.000	
Female versus transgender	3.21	0.000	

are underprivileged, deprived of adequate opportunities of earning a respectable living. Transgenders are also known

as hermaphrodite, eunuchus, hizras, and kinnar in the Indian continent. They are physiological male and have feminine gender identity. Evaluating the parameters in such patients is done keeping in mind their right to a dignified life and inclusion in the society.<sup>[12]</sup> Chandra *et al.*<sup>[2]</sup> conducted a study to evaluate the sexual dimorphism in MF and found that the average values of S-L and I-L (S-L superior border of foramen and lower border of mandible, I-L inferior border of MF and lower border of mandible) were significantly higher in males than in females. In our study, comparison of axial width between the genders using one-way ANOVA was done and found that the transgenders showed highest axial width ( $5.91 \pm 0.14$ ) followed by males ( $4.38 \pm 0.41$ ) and females ( $3.07 \pm 0.56$ ), and the difference was statistically significant ( $P < 0.05$ ). The pairwise comparison was done among the genders in which the mean differences in axial width between males and females, males and transgenders, and females and transgenders were statistically significant ( $P < 0.05$ ). Bello *et al.*<sup>[13]</sup> conducted a study to evaluate MF size, position, and symmetry in a multi-ethnic population, urban radiographic evidence and found that the vertical dimension of the mental foramina in male had larger horizontal and vertical dimensions of the foramen when compared to females which is in accordance to our study. Gungor *et al.* 2017<sup>[14]</sup> conducted a study to determine the MF locations according to gender and age in terms of the vertical distance from the surrounding anatomical structures and the vertical and horizontal size of the MF, and author found that MF location differed in males and the horizontal size of the MF was found to be less in females than males, which is similar to our study. In the present study, comparison of coronal height of MF between the genders was done by one-way ANOVA. Result showed the comparison of mean coronal height between the genders. The transgenders showed highest coronal height ( $6.83 \pm 0.31$ ) followed by males ( $4.25 \pm 0.26$ ) and females ( $3.15 \pm 0.50$ ), and the difference in coronal height between them is statistically significant ( $P < 0.05$ ). The pairwise comparison of coronal height was done among the genders where the mean differences in coronal height between males and females, males and transgenders, and females and transgenders are statistically significant ( $P < 0.05$ ).

Asrani and Shah 2018<sup>[15]</sup> conducted the study to assess the change in the position and location of MF in different age and determine the sexual dimorphism; author found that the most common appearance of MF was Type II and the shape was oval. Statistically significant differences occurred in measurements using which regressive equation for age estimation was derived for males and females which are similar to our study. In our study, comparison of tangential height between the genders using one-way ANOVA was done, to observe the mean tangential height among genders. The transgenders showed highest tangential height ( $6.74 \pm 0.32$ ) followed by males ( $4.09 \pm 0.28$ ) and females ( $3.05 \pm 0.48$ ), and the difference in tangential height between the genders was statistically significant ( $P < 0.05$ ). The pairwise comparison of tangential height was done among the genders where the mean differences in tangential height between males and females, between males and transgenders, and between females and

transgenders are statistically significant ( $P < 0.05$ ). Chappidi *et al.* 2019<sup>[16]</sup> conducted a study in South Indian population to assess the size and location of the MF and concluded that the mean size of MF as measured in the sagittal sections was found to be 3.36 mm in height and 2.54 mm in length which is in accordance to our study.

In our study, we compared tangential width between genders using ANOVA method to observe mean tangential width among genders. The transgenders showed highest tangential width ( $6.23 \pm 0.19$ ) followed by males ( $4.07 \pm 0.29$ ) and females ( $3.02 \pm 0.45$ ), and the difference in tangential width between them is statistically significant ( $P < 0.05$ ). The pairwise comparison of tangential width was done among the genders where the mean differences in tangential width between males and females, males and transgenders, and females and transgenders are statistically significant ( $P < 0.05$ ). Carruth *et al.* 2015<sup>[17]</sup> conducted the study to determine and compare the size and position of the MF using the CS 9000 CBCT unit and found that males had a significantly greater coronal height and tangential height measurement than females. In the present study, comparison of position of MF from the center of MF to the apex of the second premolar between the genders was done by one-way ANOVA which in transgenders showed highest position ( $6.47 \pm 0.36$ ) followed by males ( $5.29 \pm 0.13$ ) and females ( $4.27 \pm 0.30$ ), and the difference in position between them is statistically significant ( $P < 0.05$ ). For pairwise comparison, Tukey's *post hoc* analysis was done and found that the position among the genders where the mean differences in position between males and females, males and transgenders, and females and transgenders are statistically significant ( $P < 0.05$ ).

## CONCLUSION

It could be concluded that the axial width and coronal height of the MF show the gender dimorphism. Axial width was larger in transgenders as compared to males and females. The transgenders showed highest axial width ( $5.91 \pm 0.14$ ) followed by males ( $4.38 \pm 0.41$ ) and females ( $3.07 \pm 0.56$ ), and the difference in axial width between them is statistically significant ( $P < 0.05$ ). Tangential width is greater in transgender than males and females. The transgenders showed highest tangential width ( $6.23 \pm 0.19$ ) followed by males ( $4.07 \pm 0.29$ ) and females ( $3.02 \pm 0.45$ ), and the difference in tangential width between them is statistically significant ( $P < 0.05$ ).

World has come across many disasters such as man-made and natural. Identification of the human remains is a main and challenging job for the forensic dentist. Third gender also needs their identity to spent their life respectfully and even after death. The present study will help the forensic odontologist to think about third gender during gender identity of deceased person.

## ACKNOWLEDGMENT

I am extremely grateful to all the authors of the department of oral medicine and radiology, Triveni institute of dental sciences hospital and research center who have made



substantial contribution to the work reported in manuscript. Their encouragement, and suggestions of improvement inspired me during the completion of manuscript.

### FINANCIAL SUPPORT AND SPONSORSHIP

Nil.

### CONFLICTS OF INTEREST

There are no conflicts of interest.

### REFERENCES

1. Carvalho S, Da Silva R, Junior C, Peres A. Use of images for human identification in forensic dentistry. *J Radiol Bras* 2009;42:125-30.
2. Chandra A, Singh A, Badni M, Jaiswal R, Agnihotri A. Determination of sex by radiographic analysis of mental foramen in North Indian population. *J Forensic Dent Sci* 2013;5:52-5.
3. Malik M, Laller S, Saini SR, Mishra KR, Hora I, Dahiya N. Mental foramen: An indicator for gender determination – A radiographic study. *J Heal Sci* 2016;2:12-4.
4. Gupta V, Pitti P, Sholapurkar A. Panoramic radiographic study of mental foramen in selected dravidians of south Indian population: A hospital based study. *J Clin Exp Dent* 2015;7:e451-6.
5. Jawaid M, Iqubal MA, Shukla AK, Khan M, Farhat B. The role of CBCT in forensic dentistry. *Int J Adv Case Rep* 2014;1:179-83.
6. Alok A, Singh ID, Panat SR, Singh S, Kishore M, Jha A. Position and symmetry of mental foramen: A radiographic study in bareilly population. *J Indian Acad Oral Med Radiol* 2017;29:16-9.
7. Jasim HH. Evaluation of mental foramen location – A review. *JMCRR* 2020;3:379-85.
8. Aoun G, El-Outa A, Kafrouny N, Berberi A. Assessment of the mental foramen location in a sample of fully dentate Lebanese adults using cone beam computed tomography technology. *Acta Inform Med* 2017;25:259-62.
9. Kanchan T, Krishan K. Mental foramen in prediction of age. *J Clin Diagn Res* 2015;9:GJ01.
10. Gupta V, Pitti P, Sholapurkar A. Panoramic radiographic study of men Panoramic radiographic study of mental foramen in selected dravidians of south Indian population: A hospital based study. *J Clin Exp Dent* 2015;7:e451-6.
11. Al-Mahalawy H, Al-Aithan H, Al-Kari B, Al-Jandan B, Shujaat S. Determination of the position of mental foramen and frequency of anterior loop in Saudi population. A retrospective CBCT study. *Saudi Dent J* 2017;29:29-35.
12. Saxena E, Chandrashekhar BR, Hongal S, Torwane N, Goel P, Mishra P. A study of the palatal rugae pattern among male female and transgender population of Bhopal city. *J Forensic Dent Sci* 2015;7:142-7.
13. Bello SA, Adeoye JA, Ighile N, Ikimi NU. Mental foramen size, position and symmetry in a multi-ethnic, urban black population: Radiographic evidence. *J Oral Maxillofac Res* 2018;9:e2.
14. Gungor E, Aglarci OS, Unal M, Dogan MS, Guven S. Evaluation of mental foramen location in the 10-70 years age range using cone-beam computed tomography. *Niger J Clin Pract* 2017;20:88-92.
15. Asrani VK, Shah JS. Mental foramen: A predictor of age and gender and guide for various procedures. *J Forensic Sci Med* 2018;4:76-84.
16. Chappidi V, Swapna LA, Dheeraj V, Nikitha GR, Kanakagiri M. Evaluation of morphometric variations in mental foramen and prevalence of anterior loop in South Indian population – A CBCT study. *J Indian Acad Oral Med Radiol* 2019;31:134-9.
17. Carruth P, He J, Benson BW, Schneiderman ED. Analysis of the size and position of the mental foramen using the CS 9000 cone-beam computed tomographic unit. *J Endod* 2015;41:1032-6.