



**Evaluation And Comparison of Wound Healing Properties of Platelet Rich Fibrin Membrane and Non-Eugenol Periodontal Dressing After Gingival Depigmentation Using Laser - A Clinical Study**

<sup>1</sup>Dr. Lipsa Surovita, Post graduate student, Department of Periodontology and Oral Implantology Triveni Institute of Dental Sciences Hospital and Research Centre Bilaspur, Chhattisgarh, India.

<sup>2</sup>Dr. Raja Sridhar, Prof. & HOD, Department of Periodontology and Oral Implantology Triveni Institute of Dental Sciences Hospital and Research Centre Bilaspur, Chhattisgarh, India.

<sup>3</sup>Dr. Sudeep HM, Prof, Department of Periodontology and Oral Implantology Triveni Institute of Dental Sciences Hospital and Research Centre Bilaspur, Chhattisgarh, India.

<sup>4</sup>Dr. Anwasha Das, Post graduate student, Department of Periodontology and Oral Implantology Triveni Institute of Dental Sciences Hospital and Research Centre Bilaspur, Chhattisgarh, India.

<sup>5</sup>Dr. Elashri Chatterjee, Reader, Department of Periodontology and Oral Implantology Triveni Institute of Dental Sciences Hospital and Research Centre Bilaspur, Chhattisgarh, India.

**Corresponding Author:** Dr. Lipsa Surovita, Post graduate student, Department of Periodontology and Oral Implantology Triveni Institute of Dental Sciences Hospital and Research Centre Bilaspur, Chhattisgarh, India.

**Citation of this Article:** Dr. Lipsa Surovita, Dr. Raja Sridhar, Dr. Sudeep HM, Dr. Anwasha Das, Dr. Elashri Chatterjee, “Evaluation and Comparison of Wound Healing Properties of Platelet Rich Fibrin Membrane and Non-Eugenol Periodontal Dressing After Gingival Depigmentation Using Laser - A Clinical Study”, IJDSIR- May - 2022, Vol. – 5, Issue - 3, P. No. 202 – 209.

**Copyright:** © 2022, Dr. Lipsa Surovita, et al. This is an open access journal and article distributed under the terms of the creative commons attribution non-commercial License. Which allows others to remix, tweak, and build upon the work non-commercially, as long as appropriate credit is given and the new creations are licensed under the identical terms.

**Type of Publication:** Original Research Article

**Conflicts of Interest:** Nil

**Abstract**

The gingiva is considered to be the most frequently pigmented region of the oral cavity. Gingival depigmentation carried out using periodontal plastic surgery, scalpel method, cryosurgery, electrosurgery, laser technique, abrasion technique to remove the melanin hyperpigmentation for aesthetic concerns. Among this laser technique has been recognized as one of the most effective, comfortable and reliable technique for gingival depigmentation. Depigmentation procedure

leads to exposure of raw connective tissue, necessitating to cover this tissue to minimize likelihood of post operative bleeding, healing by preventing surface trauma by use of Zinc oxide with or without Eugenol like Ward’s Wondrpak & Coe-Pak respectively, Cellulose based dressings like Reso Pac, Polyether Di methacrylate like Barricade. Despite the aforementioned advantages, none of the materials have a direct role in the healing of gingival tissues. Recently the introduction of biological wound dressing such as amniotic

.....  
**Corresponding Author:** Dr. Lipsa Surovita, *ijdsir*, Volume – 5 Issue - 3, Page No. 202 - 209

membrane, chorion membrane, first generation and second-generation Platelet concentrates in the field of periodontics has gained importance materials. Especially platelet rich fibrin developed by Choukroun et al in 2001 has risen to prominence because of its faster wound healing ability and numerous growth factors. The aim of the present study was to ascertain the clinical benefits of Platelet Rich Fibrin with Non-Eugenol periodontal dressing over non-Eugenol periodontal dressing only, in wound healing after gingival depigmentation procedure. The present split mouth study was conducted in 42 sites in a total of 21 patients divided into 2 groups of 21 sites in each group where Group A (Platelet Rich Fibrin and Non-Eugenol periodontal dressing) Group B (Non-Eugenol periodontal dressing) using Healing index and pain assessment on 3rd and 5th day followed by epithelization test on 5th day with toluidine blue. Overall, the result of the present study also depicts the beneficial effects of PRF in terms of patient comfort, faster healing of treated depigmentation sites.

### Summary

Sites of Group A & B showed significant lower pain and improved healing on 3rd and 5th post operative day. Further when compared, pain assessment score showed no significant difference between the groups. Though both groups showed improved healing & epithelization group A (PRF + NEPD) demonstrated significant higher healing and epithelization index score at 3rd and 5th post operative day with mild staining indicating presence of lesser inflammatory cells than for group B (NEPD) which showed severe staining indicating more inflammation at 5th day. This implies that PRF aids in protecting raw wound with better patient comfort and faster healing properties than the sites treated with non-eugenol dressing.

**Keywords:** depigmentation, non-eugenol periodontal dressing, platelet rich fibrin.

### Introduction

Melanin hyperpigmentation of the gingiva does not pose any medical problem but the ever-increasing demand for a pleasing personality, especially a beautiful smile, has made many young individuals more conscious of any dark patches of pigmentation, especially on the facial aspects of the gingiva, in the anterior region particularly in the patients having excessive gingival display or gummy smile. Gingival melanin hyperpigmentation can be divided into physiologic (racial) or pathologic (manifestation of systemic disease) and can be endogenous (Diabetes, Hyperthyroidism, Addison's disease, Peutz-Jegher syndrome, HIV infection, Tuberculosis, Candidiasis)<sup>1</sup> or exogenous (exposure to UV light, drug-related, chemical, amalgam tattoo etc)<sup>2</sup>. The most common melanin pigmentation occurs as a diffuse, deep purplish to brown discoloration which can be uniform or patched.<sup>3</sup>

Melanocytes constitute a heterogeneous group of cells. These unicellular dendritic cells lodge in the basal cell layer of the epidermis and oral epithelium, synthesizing melanin in organelles called melanosomes by the process of melanogenesis. The process of pigmentation consists of three phases.<sup>4</sup>

- The activation phase occurs when the melanocytes are stimulated by factors like stress hormones, sunlight etc. causing production of chemical messengers like melanocyte stimulating hormone.
- In synthesis phase, melanocytes make granules called melanosomes. Tyrosinase (TYR) carries out tyrosine hydroxylation to L-3, 4-dihydroxy phenylalanine (DOPA) which is oxidized to DOPA quinone which form pheomelanin and eumelanin.



- In expression phase, melanosomes are transferred from the melanocytes.

Various treatment modalities scalpel, laser technique, abrasion method, soft tissue autograft and cryosurgery have been employed for gingival depigmentation.

Lasers have been widely used in medicine and surgery; different lasers have been used for gingival depigmentation. Laser photon energy has been shown to be absorbed by tissue elements called chromophores composed of melanin, haemoglobin, allied pigmented proteins, hydroxyapatite, and water. Thus resulting in thermal interaction as they produce heat and increase the kinetic energy of the affected tissue along with effects such as coagulation, vaporization, necrosis, carbonization and denaturation of the tissue. As depigmentation technique leaves a raw wound use of periodontal dressing is necessary to cover the wound. Periodontal dressings were first introduced by Dr. A.W Ward in 1923 .The use of periodontal dressing is beneficial as it not only protects the wound from mechanical trauma but also provides stability of the surgical site during the healing process. Apart from these most important other advantages include: patient comfort during tissue healing after surgery, prevention of post-operative hemorrhage, decreasing tooth hypersensitivity in the first hours after surgery, protecting the clot from the forces applied during speaking or chewing, preventing gingival detachment from the root surface, protection of denuded bone during the healing process and splinting of mobile teeth after surgery.<sup>5</sup> Despite all the aforementioned advantages, however retention of pack at the surgical site ,absence of healing properties and abundant plaque accumulation under surface leading to delayed healing has led to scout out other options.

Recently the introduction of concept of biological wound dressing (amniotic membrane, chorion membrane, first generation and second-generation Platelet Concentrates) in the field of periodontics has been captivating the attention of many researchers. Among these biological wound dressing, the use of platelet rich fibrin a second generation Platelet Concentrates developed by Choukroun in 2001<sup>6</sup> gained importance because of the biologic effects of the PRF membrane which is divided into 4 main aspects of healing that are angiogenesis, immune control, harnessing the circulating stem cells and wound protection by epithelial cover.<sup>7</sup>

The present study was undertaken to evaluate the clinical benefits of Platelet Rich Fibrin as a periodontal dressing over non-Eugenol periodontal dressing after gingival depigmentation procedure.

#### **Material and Methods**

This study is a Randomised controlled clinical trail, in which a total of 21 gingival pigmentation subjects between 16 and 30 years of age were selected from those attending the department of Periodontics and department of Oral Medicine at Triveni Institute of Dental Sciences, Hospital and Research Centre, Bilaspur, Chhattisgarh. Subjects were selected on the basis of the following inclusion and exclusion criteria.

#### **Inclusion criteria**

- Pigmented gingiva on labial surface of maxillary and mandibular arch with dummette score 3 and 4
- Free of inflammation
- Thick biotype
- $\geq 2$ mm of attached gingiva

#### **Exclusion criteria**

- Severe acute or chronic systemic disease
- Periodontal therapy within 6 months

- Under antibiotics medication for my chronic inflammatory condition
- Use of any form of tobacco
- Pregnant and lactating females
- Patient having teeth with inadequate endodontic treatments
- Gingival recession.

A total of 42 sites with diffuse gingival pigmentation on maxillary and mandibular anterior sextant region based on inclusion and exclusion criteria were chosen for the study. Two groups were formed for the study

Group A comprises of 21 sites with diffuse gingival pigmentation and received PRF with Non-Eugenol periodontal dressing (NEPD) after depigmentation with laser.

Group B comprises of 21 sites with diffuse gingival pigmentation and received non-Eugenol periodontal dressing (NEPD) alone after depigmentation with laser.

The following clinical parameters were recorded

Pain assessment at the treated site (0- no pain and 1- pain), Healing Index (Landry, Trunbull, Howley 1988), Epithelization test using toluidine blue.

#### Treatment Protocol

Under aseptic condition, subjects were anesthetized with 2% lignocaine with adrenaline 1:200000 followed by depigmentation procedure in maxillary or mandibular arch anterior sextant using Laser technique with the help of 3-watt diode laser (ZOLAR) at 980 nm wavelength was applied at 1.5-watt power output in a contact mode. The procedure includes emission of laser on pigmented area of the gingiva and hence removing the epithelial lining thus allowing the denuded connective tissue to heal by secondary intention. PRF was prepared according to the recommended protocol by Choukroun et al 9 mL of blood was withdrawn from the antecubital vein of the participating subjects and was transferred to

glass test tubes for centrifugation in REMI(AVI555) centrifugation machine at rpm of 2700 for 12 min. The gel obtained as a result of centrifugation was compressed using PRF magic box to obtain membrane (Fig 1a-d) and placed at Group A (PRF+NEPD) (Fig 2a, b) and Group B (NEPD alone) (Fig 2b).

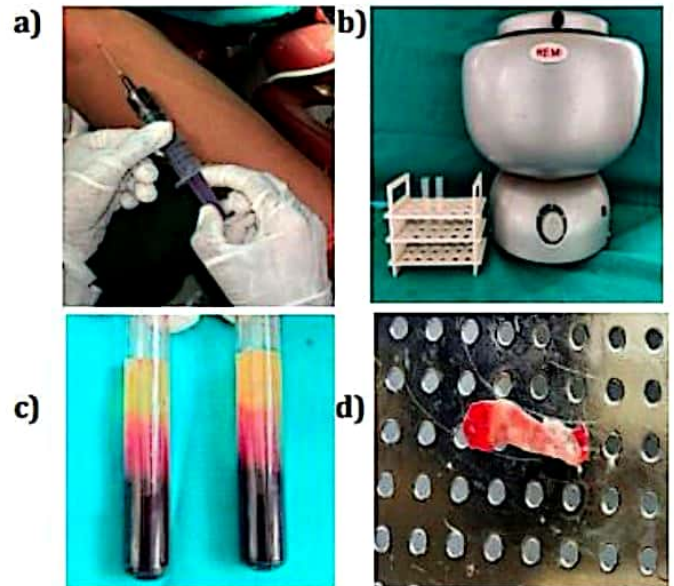


Fig 1: a) withdrawing of 9ml blood; b) REMI(AVI555) centrifugation machine; c) PRF after centrifugation; d) PRF membrane placed on magic box.

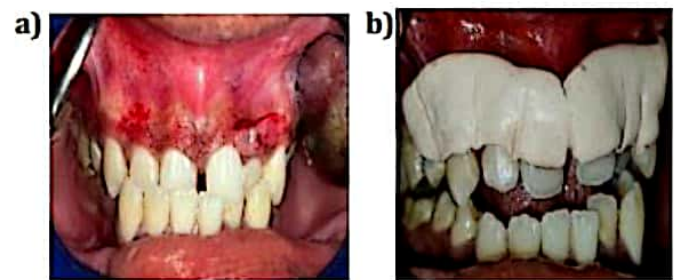


Fig 2: a) PRF placed at surgical site b) Non eugenol dressing at surgical site.

The subjects were then recalled on 3rd post operative day for pain assessment and healing index (Fig 3a) and on 5 th day along with pain assessment and healing index, epithelization test (Fig 3b) was performed.



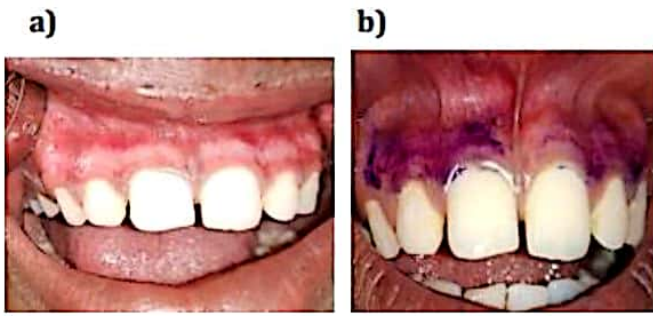


Fig 3: a) post operative 3rd day after depigmentation b) epithelization test on 5th post operative day

### Result

Table 1 reveals a mean age distribution of  $23.67 \pm 4.6$  and  $23.71 \pm 4.58$  for Group A and B respectively without any significant difference between the groups. Similarly, there was no significant difference between the groups for gender. (Table 1)

Table 2 shows the mean pain assessment scores reduced from  $0.52 \pm 0.68$  to  $0.1 \pm 0.3$  in group A, group B also showed a decrease in scores from  $0.62 \pm 0.74$  to  $0.14 \pm 0.36$ . This difference in both groups remained significant ( $p=0.011$ ) (Table 2).

Table 3a shows on 3rd post operative day 11(52.38%) subjects demonstrated 'good healing' of tissue followed by 9(42.86%) subjects with very good healing response Only 1(4.76%) individual showed poor. On the 5th day 11 subjects (52.38%) showed very good healing and 10 subjects (47.62%) showed excellent healing. The overall healing response of the subjects in group A when compared from the 3rd day to the 5th day was highly significant (p value of  $<0.0001$ ) Table 3a)

Table 3b shows On 3rd post operative day, 16 (76.19%) subjects demonstrated a good healing response followed by 5(23.81%) subjects with poor healing On the 5th post operative day while 17 subjects (80.95%) had very good healing of tissue, 4 subjects (19.05%) showed good healing response. None of the subjects showed excellent healing. The overall healing response of the subjects in

group B when compared from the 3rd day to the 5th day was highly significant( $p<0.0001$ ) Table 3b)

Table 4 shows Subjects in group A experienced less pain than subjects in group B on the 3rd and the 5th day with mean score of group A being  $0.52 \pm 0.68$  &  $0.1 \pm 0.3$  respectively and in group B being  $0.62 \pm 0.74$  &  $0.14 \pm 0.36$  respectively, results revealed no significant difference between the groups. (Table 4)

Table 5 a&b shows a total of 9 subjects (42.86%) demonstrated very good healing response of the tissue on the 3rd day and the number increased to 17 subjects (80.95%) for the same on the 5th post operative day. In Group B subjects 17(80.95%) of them displayed very good healing response on Day 5. Good healing of the tissues was seen in 11subjects (52.38%) and 16 subjects (76.19%) in group A & B respectively on Day 3. On Day 5, there was a drastic improvement in the tissue healing as subjects of Group A either demonstrated very good 11 subjects (52.38%) or excellent 10 subjects (47.62%) healing response of the tissues. Though 1 subject (4.76%) in group A and 5 subjects (23.81%) in group B demonstrated poor healing response on Day 3. While on 5th day 10 subjects (47.62%) in Group A had excellent healing tissue response. Overall, the comparison of healing index scores between the groups statistically highly significant at both 3rd and 5th day where Group A subjects demonstrated higher Healing Index Scores.  $p = 0.002$  and  $p=0.0005$  respectively (Table 5a and 5b) Table 6 15 subjects (71.43%) in Group A showed mild staining (good healing), only 1 subject in Group B (4.76%) displayed mild staining. On the other hand, majority of Group B subjects i.e 16 (76.19%) of them showed moderate staining indicating fair healing and 6 subjects (28.57%) in Group A showed moderate staining, 4(19.05%) subjects in Group B showed severe staining indicating poor healing. Again,

Group A subjects displayed a highly significant result for epithelization test ( $p < 0.0001$ ) Table 6)

Table 1 Distribution of age and gender in Group A and Group B

	GROUP A (PRF+ NON EUGENOL DRESSING)	GROUP B (NON EUGENOL DRESSING)	p value
AGE (MEAN ± SD)	23.67±4.6	23.71±4.58	0.97 NS
MAL E: FEMALE	10(47.62%):11(52.38%)	10(47.62%):11(52.38%)	1.00 NS

Table 2: Intragroup assessment for pain between 3rd and 5th post operative day

PAIN ASSESSMENT	GROUP A (PRF + NON EUGENOL DRESSING)	GROUP B (NON EUGENOL DRESSING)
AT THIRD DAY	0.52±0.68	0.62±0.74
AT FIFTH DAY	0.1±0.3	0.14±0.36
p value	0.011 S	0.011 S

Table 3: Intragroup assessment of healing index score at post operative 3rd and 5th day Table 3a: Group A

GROUP A (PRF + NON EUGENOL DRESSING)	HEALING INDEX SCORE AT 3 <sup>rd</sup> DAY	HEALING INDEX SCORE AT 5 <sup>th</sup> DAY
VERY POOR	0(0%)	0(0%)
POOR	1(4.76%)	0(0%)
GOOD	11(52.38%)	0(0%)
VERY GOOD	9(42.86%)	11(52.38%)
EXCELLENT	0(0%)	10(47.62%)
TOTAL	21 (100%)	21 (100%)

chi square value=22.2 p value<0.0001 HS

Table 3b: Group B

GROUP B (NON EUGENOL DRESSING)	HEALING INDEX SCORE AT 3 <sup>rd</sup> DAY	HEALING INDEX SCORE AT 5 <sup>th</sup> DAY
VERY POOR	0(0%)	0(0%)
POOR	5(23.81%)	0(0%)
GOOD	16(76.19%)	4(19.05%)
VERY GOOD	0(0%)	17(80.95%)
EXCELLENT	0(0%)	0(0%)
TOTAL	21 (100%)	21 (100%)

Table 4: Intergroup assessment for pain at post operative 3rd and 5th day between Group A and Group B

PAIN ASSESSMENT	GROUP A (PRF + NON EUGENOL DRESSING)	GROUP B (NON EUGENOL DRESSING)	p value
AT THIRD DAY	0.52±0.68	0.62±0.74	0.66 NS
AT FIFTH DAY	0.1±0.3	0.14±0.36	0.64 NS

Table 5a: Intergroup assessment of Healing Index score at post operative 3rd day between Group A and Group B

HEALING INDEX SCORE AT 3 <sup>rd</sup> DAY	GROUP A (PRF + NON EUGENOL DRESSING)	GROUP B (NON EUGENOL DRESSING)
VERY POOR	0(0%)	0(0%)
POOR	1(4.76%)	5(23.81%)
GOOD	11(52.38%)	16(76.19%)
VERY GOOD	9(42.86%)	0(0%)
EXCELLENT	0(0%)	0(0%)
TOTAL	21 (100%)	21 (100%)



Chi square value=12.59 p value=0.002 HS

Table 5b: Intergroup assessment of Healing Index score at post operative 5th day between Group A and Group B

HEALING INDEX SCORE AT 5 <sup>th</sup> DAY	GROUP A (PRF + NON EUGENOL DRESSING)	GROUP B (NON EUGENOL DRESSING)
VERY POOR	0(0%)	0(0%)
POOR	0(0%)	0(0%)
GOOD	0(0%)	4(19.05%)
VERY GOOD	11(52.38%)	17(80.95%)
EXCELLENT	10(47.62%)	0(0%)
TOTAL	21 (100%)	21 (100%)

Chi square value=15.28 p value=0.0005 HS

Table 6: Intergroup assessment of epithelization test at post operative 3rd and 5th day between Group A and Group B

EPITHELIZATION TEST	GROUP A (PRF+ NON EUGENOL DRESSING)	GROUP B (NON EUGENOL DRESSING)
MILD STAINING(GOOD HEALING)	15(71.43%)	1(4.76%)
MODERATE STAINING( FAIR HEALING)	6(28.57%)	16(76.19%)
SEVERE STAINING (POOR HEALING)	0(0%)	4(19.05%)
TOTAL	21 (100%)	21 (100%)

Chi square value=20.79 p value<0.001HS

Discussion Jani ani et al observed the difference in gingival melanin pigmentation and their intensity across different age groups.<sup>8</sup> This fair distribution of age and gender may play an important role in some aspects of periodontal treatment, healing outcomes or even recurrence after periodontal plastic procedures. (Table 1)

Intra group pain assessment score on 3rd and 5th post operative day was in accordance to the study by Hegde et al <sup>9</sup> where Visual analogy score eventually lowered for laser treated patient. Pain reduction after depigmentation using lasers could be attributed to the protein coagulum that is formed on wound surface thereby acting as a biologic dressing. In addition it may be the result of the sealing of the ends of sensory nerves. (Table 2). Both groups displayed significantly good healing of the tissues post depigmentation (Table 3a 3b) This could be due to healing by secondary intention and healing by laser results in thermal coagulation and denaturation of some vasculogenic polypeptides.

Group A (PRF+NEPD) demonstrated significantly higher healing index score operative day along with less inflammatory cell infiltrate on 5th day (Table 5a,5b,6). Accordance to Dahiya et al <sup>10</sup> and Bansal et al, <sup>11</sup> PRF can be attributed to its inherent features like angiogenesis, support to immunity, and epithelial cover that is elaborated as follows:<sup>12</sup>

**Conclusion**

Within the limitation of the study, it can be concluded that the application of PRF showed a successful approach to protect the raw wound area of depigmentation sites along with the sign of benefits including

- Accelerated healing process
- Release of growth factors
- Lesser pain
- better patient comfort

However a larger sample size and longer follow up is required to assess the beneficial properties of PRF as a dressing to cover raw wound areas after procedures such as depigmentation; including its influence on the time interval taken for regimentation of the treated sites.

## References

1. C. Sreeja et al K. Ramakrishnan, D. Vijayalakshmi, M. Devi, I. Aesha and B. Vijaya Banu. Oral pigmentation: A review, J Pharm Bio allied Sci. 2015 Aug; 7(Suppl 2): S403–S408.
2. Ansari WN, Muglikar SD, Ghodke PS, Hegde RV, Sheikh S, Badaam H. Gingival Depigmentation Using CO2 Laser and Scalpel Technique with PRF Membrane- A Clinical and Histological Study. Dentistry 2020;10(6): 563.
3. Clifton O. and Dummett. A Classification of Oral Pigmentation. Military Medicine October, 1962.
4. Shahna N, Dr. Suchetha A, Sapna N, Darshan BM and Apoorva SM. Gingival pigmentation: A review of literature. International Journal of Applied Dental Sciences 2019; 5(2): 83-91
5. Harpenan LA. Periodontal dressing. In: Hall WB, ed. Critical Decisions in Periodontology, 4th ed. Ontario: BC Decker; 2003. p. 280-1.
6. Choukroun J, Diss A, Simonpieri A, Girard MO, Schoeffler C, Dohan SL, Dohan AJ, Mouhyi J, Dohan DM. Platelet-rich fibrin (PRF): a second-generation platelet concentrate. Part V: histologic evaluations of PRF effects on bone allograft maturation in sinus lift. Oral Surg Oral Med Oral Pathol Oral Radiol Endod. 2006 Mar;101(3):299-303.
7. Van Heinsberg VW, Coenen A, Koolwijk P. Role of fibrin matrix in angiogenesis. Ann N Y Acad Sci. 2001; 936:426-37.
8. Janiani P, Bhat PR, Trasad VA, Acharya AB, Thakur SL. Evaluation of the intensity of gingival melanin pigmentation at different age groups in the Indian population: An observational study. J Indian Soc Pedod Prev Dent. 2018 Oct-Dec;36(4):329-333.
9. Hegde R, Padhye A, Sumanth S., Jain A. S, Thukral N. Comparison of Surgical Stripping; Erbium-Doped: Yttrium, Aluminium, and Garnet Laser; and Carbon Dioxide Laser Techniques for Gingival Depigmentation: A Clinical and Histologic Study. J Periodontol 2013; 84:738-748
10. Dahiya R, Blaggana A, Panwar V, Kumar S Kathuria A, Malik S. Clinical and histological comparison of platelet rich fibrin versus non-eugenol periodontal dressing in the treatment of gingival hyperpigmentation. J Indian Soc Periodontal 2019; 23:345-50
11. Bansal M, Kumar A, Puri K, Manish K, Gupta G, Vij H. Clinical and histologic evaluation of platelet rich fibrin accelerated epithelization of gingival wound. J Cut an Esthet Surg. 2016 Jul-Sep;9 (3):196-200
12. Choukroun J, Diss A, Simonpieri A, Girard MO, Schoeffler C, Dohan SL, Dohan AJ, Mouhyi J, Dohan DM. Platelet-rich fibrin (PRF): a second-generation platelet concentrate. Part IV: clinical effects on tissue healing. Oral Surg Oral Med Oral Pathol Oral Radiol Endod. 2006 Mar;101(3): e56-60