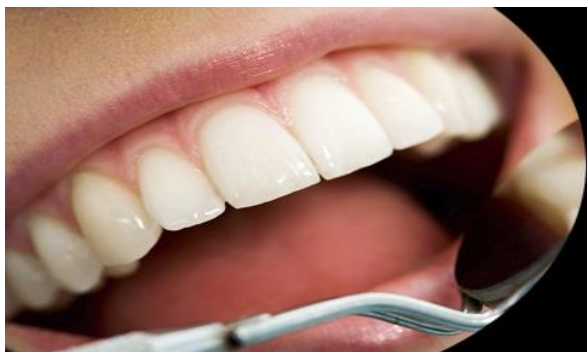



ISSN Print: 2394-7489
ISSN Online: 2394-7497
IJADS 2021; 7(2): 453-456
© 2021 IJADS
www.oraljournal.com
Received: 22-02-2021
Accepted: 24-03-2021

Dr. Avinash Sagvekar
Pravara University of Medical
Sciences Rural Dental College
and Hospital, MDS in
Prosthodontics Department,
Deemed University, Loni,
Maharashtra, India

Dr. Aushili Mahule
Dadasaheb Kalmegh Smruti
Dental College and Hospital,
MDS, Department of
Prosthodontics and
Implantology, MUHS, Nagpur,
Maharashtra, India

Dr. Sachin Fulbel
Shri. Yashwantrao Chavan
Memorial Medical & Rural
Development Foundation's
Dental College & Hospital,
MDS in Periodontology
Department, MUHS, Nashik,
Maharashtra, India.=

Corresponding Author:
Dr. Avinash Sagvekar
Pravara University of Medical
Sciences Rural Dental College
and Hospital, MDS in
Prosthodontics Department,
Deemed University, Loni,
Maharashtra, India

Complete denture by neutral zone technique in a severely resorbed mandibular alveolar ridge: A case report

Dr. Avinash Sagvekar, Dr. Aushili Mahule and Dr. Sachin Fulbel

DOI: <https://doi.org/10.22271/oral.2021.v7.i2g.1247>

Abstract

Persistent complete denture wearer patients many a time face a problem of instability of their mandibular complete denture due to high resorption rate of lower edentulous ridge in comparison to maxilla. When denture is fabricated in a zone where the forces of lip, cheeks, tongue and modulus are in balance, then the denture will be stable and retentive more effectively during function. This zone is called as neutral zone. It becomes a duty of a prosthodontist to effectively place the denture in neutral zone, which facilitates near normal function. This technique is used to minimize the displacing forces of the surrounding structures, which is achieved by functional impression technique used to solve the problem of lower denture instability.

Keywords: neutral zone, denture stability, functional impression technique

Introduction

Complete dentures is a mechanical devices that performs a functional activity in the oral cavity, the teeth arrangement and polish surface of denture must be in an appropriate and acceptable manner so that they are in harmony with the all intra oral and extra oral muscular functions. All oral functions, such as talking, eating, whistling, deglutition, smiling, and laughing, involving the interactions between tongue, lips, cheeks, and floor of the mouth. The goal of a Prosthodontist should be restoring the form, functions and esthetics of the patient. Fish picked up one out of other three surfaces of the denture that is polished surface which is bounded by the tongue and the cheeks ^[1]. In 1931 Wilfred Fish of England introduced neutral zone concept. What is neutral zone? It is the potential space between the lips and cheeks on one side and the tongue on other, that area where forces between the tongue and cheeks or lips are equal. So in simple words neutral zone is that area having zero intra oral muscular forces ^[2] Russell Tench ^[3] Many others ^[4-9], including Perry helped to rise up this concept theoretically as well as in practical procedures.

In complex cases where surgical implant procedures are contraindicated the neutral zone impression technique is the only option for the stabilizing the complete denture for its function. It is not only a choice of treatment in atrophic mandibular residual ridge but also in patients with partial glossectomy, hemi-mandibulectomy or imbalanced neuromuscular function of the tongue and intraoral muscle which ultimately gives rise to atypical movement or an unfavourable denture bearing area. Hence this Technique is carried out as an alternative method of complete denture construction in completely resorbed ridge cases.

Case report

A male patient aged 76 years reported to 32 Dental Bites and Implant Centre (Mumbai), with the chief complaint of loose mandibular complete denture. Patient had been edentulous for the past 15 years. He came to seek dental treatment because he was not satisfied with the previous set of dentures as it has the problem of instability of mandibular denture. On intra oral examination, it was observed that completely edentulous maxillary and mandibular arch, strong buccinator and mentalis muscle that narrows labial and buccal sulcus on activation.

V shaped mandibular ridge. Due to excess resorption of alveolar ridge muscle attachments were higher and close to the residual ridge [Figure 1].

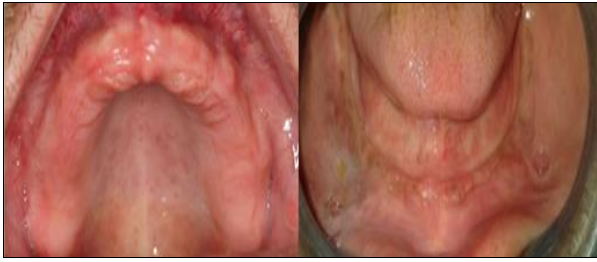

Fig 1: Intraoral photos of maxillary and mandibular occlusal view and front view

Meticulous examination of previous denture showed posterior teeth was placed way too far on lateral crest of ridge. The mandibular occlusal plane was also higher giving rise to instability of mandibular denture. It was therefore decided to fabricate the denture in neutral zone technique to determine the optimum position of teeth and contour the polished surfaces of denture in harmony with the surrounding musculature.

Preliminary impressions were made for both maxillary and mandibular arch in stock trays. Type I medium fusing impression compound for maxillary and admix method 3:7 ratio of medium fusing impression compound and low fusing green stick impression stick [Figure 2] which was further poured in Type II gypsum product to obtain diagnostic casts.

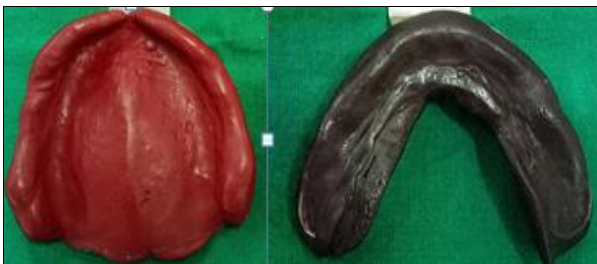

Fig 2: Maxillary and mandibular preliminary impressions

Border moulding procedure was done using low fusing impression material and final wash impression was made in low viscosity mucostatic zinc oxide eugenol impression material

Impression was poured in Type III dental stone to obtain master casts [Figure 3].

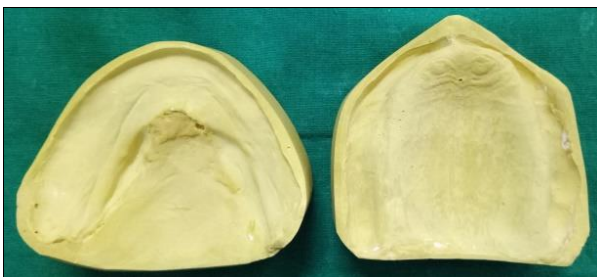

Fig 3: Maxillary and mandibular master casts

Both the record base were fabricated in heat cured acrylic resin material (DPI) to increase extension, comfort and stability. The maxillary occlusal rim was properly shaped to provide good support for labial and buccal musculature. Centric jaw relation was recorded and face bow transferred to

Hanau semi adjustable articulator using face bow [Figure 4].

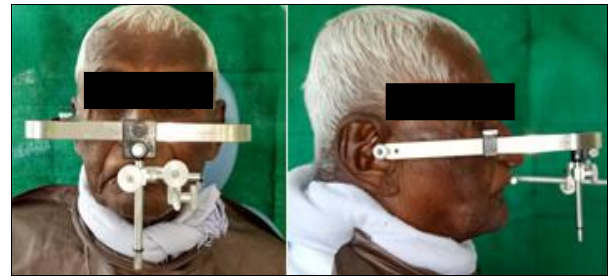

Fig 4: Face bow transfer

Wax of Mandibular occlusal rim was completely peeled off and dumbbell shaped self-cure acrylic stent were attached over the mandibular record base in relation with recorded vertical height. Maxillary occlusion rim and modified mandibular record base with dumbbell shaped acrylic stent were evaluated intra orally for their fit & ensured that acrylic stent do not interfere with muscle movement during functional movements [Figure 5].

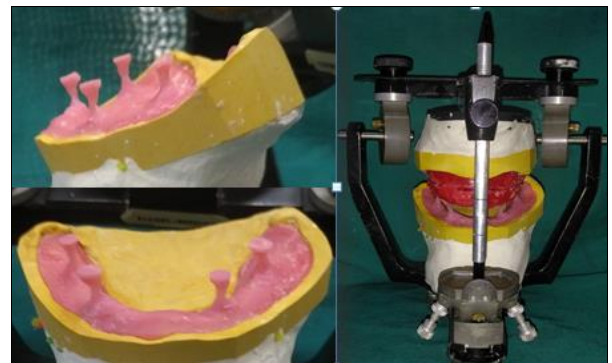


Fig 5: Dumbbell shaped acrylic stents on mandibular record base

Maxillary rim was retained inside the mouth providing support to the facial muscle during making of neutral zone. Before starting with the neutral zone procedures, the patient shoulders were made relaxed with the head unsupported. Maxillary wax rim which was left inside the mouth was checked for support & occlusal plane. The medium fusing impression compound and low fusing green stick in ratio 3:7 (KERR) was softened in a 63 to 65°C water bath. The softened compound was properly kneaded and rolled over the attached acrylic stents on record base at recorded vertical dimension. Next to bring the muscle in action patient was asked to repeat series of actions like whistling, speaking, pursing the lips, swallowing, sucking, sipping water and slightly protruding the tongue out. These actions were performed repeatedly simulating physiological functioning. After 5 minutes, the set impression was taken out from the mouth. The neutral zone impression obtained was transferred on the master cast [figure 6].

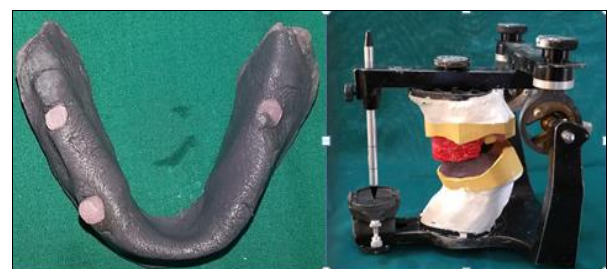

Fig 6: Neutral zone recorded

Locating grooves were cut on the master cast and indexing was done with type II gypsum product around the neutral zone impression on both the labial and lingual sides. The compound occlusal rim and acrylic stents was then replaced by flowing the molten wax in between the index to obtain wax rim in the neutral zone. Mandibular teeth arrangement was initiated in the neutral zone area then maxillary teeth were arranged according to neutral zone relation. Position of the teeth was checked by placing the plaster index together around the wax try in. [figure. 7].

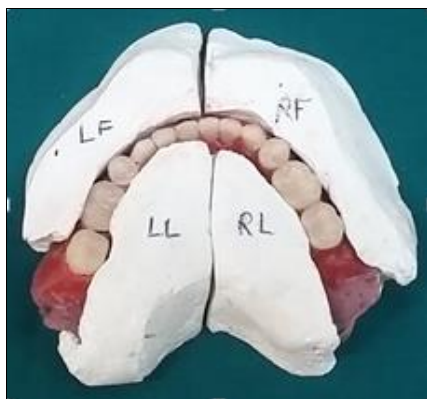

Fig 7: Teeth arrangement in neutral zone with plaster index

The influence of perioral and oral muscle group were once again confirmed using low fusing zinc oxide eugenol. [figure. 8].

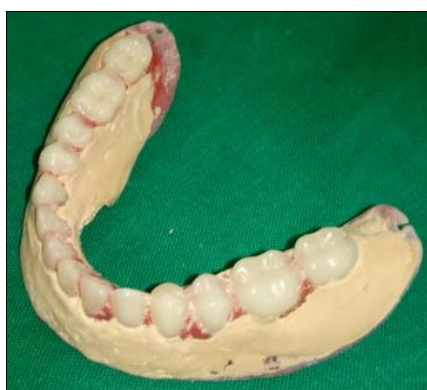

Fig 8: Intra oral re-confirming the teeth arrangement in neutral zone

The denture was stable after all the movements. Aesthetics, phonetics and occlusion were assessed. Next denture fabrication was done in heat cure acrylic resin by conventional method. Finished, polished denture was then placed inside the patient's mouth after doing minor occlusal corrections. [figure. 9].

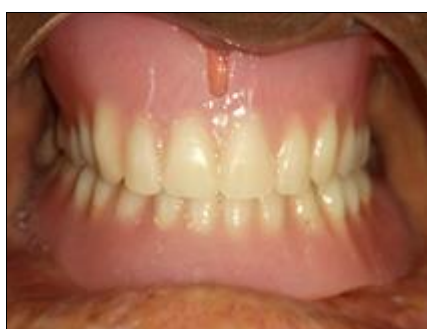

Fig 9: Final denture insertion

Post denture insertion and related instructions were given to the patient and recalled after 24 hours for 1st check-up followed by 1 week, 1 month, 3 months, 6 months and 1 year.

Discussion

The technique of neutral zone described in this article is simple but technique sensitive to record the physiological dynamics of perioral muscular functions. A complete denture is determined by detail information that provides contours and position of denture teeth. There are same principles of the neutral zone concept since it has been described. Although, this technique has various modifications, which includes impression materials used to record the detail, and also in terms of the functional movements and refining the initial records. For example:

1. Without inserting the upper record base, the neutral zone impression can be made by using impression compound as occlusal rim to record the neutral zone contour before the final impression is completed [10, 11, 12].
2. After the final impression is made, confirming vertical dimension in occlusal, the neutral zone is recorded with a special recording base and maxillary wax rim at the selected vertical dimension [13, 14].
3. Smoothing of the polished surface of the trial wax denture with the impression material [15] or relining the polished surface of delivered denture by the functional impression activities. All the methods can be combined or individually used according to the clinician's preference.
4. Also the material used for recording neutral zone should be reasonably slow setting to allow the oral parafunctional musculature to shape it to the appropriate contour and dimensions. Artificial teeth to be arranged within the neutral zone to achieve two important objectives: No interfere seen between prosthetic teeth and normal muscle Function and perioral muscle activity imparting force against the complete dentures that serves to stabilize and retain the prostheses rather than causing denture to displace.

Conclusion

New innovations, advance dental materials and development of newer techniques in prosthetic dentistry have proven greater success in stability, support and retention of denture. The neutral zone impression technique should be incorporated into fabrication of every complete denture though it is indicated in patients with severe residual ridge resorption; the procedures discussed can also be useful in edentulous patients with dental implants.

Acknowledgements

The final outcome of this Neutral zone technique would not have been possible without the dedication and efforts of Mr. Bharat Sagvekar (Master Dental Technician) and Nova Dental Art team.

References

1. Fish EW. An analysis of the stabilizing force in full denture construction. *Br Dent J* 1947;83:137-42.
2. The glossary of prosthodontic terms. *J Prosthet Dent* 2005;94:10-92.
3. Tench RW. Personal communication 1952.
4. Cavalcanti AA. Personal communication 1962.
5. Brill N, Tryde G, Cantor R. The dynamic nature of the lower denture space. *J Prosthet Dent* 1965;15:401-418.

6. Lammie GA. Aging changes in the complete lower denture. *J Prosthet Dent* 1956;6:450-464.
7. Raybin NH. The polished surface of complete dentures. *J Prosthet Dent* 1963;13:236-41.
8. Lott F, Levin B. Flange technique, an anatomic and physiologic approach to increased retention, function, comfort, and appearance of denture. *J Prosthet Dent* 1996;16:394-413.
9. Victor Beresin E. The neutral zone in complete dentures. *J prosthet dent* 2006;95:93-100.
10. Cagna DR, Massad JJ, Schiesser FJ. The neutral zone revisited: from historical concepts to modern application. *J Prosthet Dent* 2009;101:405-412.
11. Beresin VE, Schiesser FJ. The neutral zone in complete dentures. *J Prosthet Dent* 1976;36:356-367.
12. Fahmy FM, Kharat DU. A study of the importance of the neutral zone in complete dentures. *J Prosthet Dent* 1990;64:459-462.
13. Wright SM. The polished surface contour: A new approach. *Int J Prosthodont* 1991;4:159-163.
14. Gahan MJ, Walmsley AD. The neutral zone impression revisited. *Br Dent J* 2005;198:269-272.
15. Lynch CD, Allen PF. Overcoming the unstable mandibular complete denture: The neutral zone impression technique 2006;33:21-22, 24-26.