

## Treatment of a Intraosseous Defect with Platelet-rich fibrin (PRF) – A case report

Dr. Yogesh Goswami<sup>1</sup>, Dr. Richa Mishra<sup>2</sup>, Dr. Abhay.P.Agrawal<sup>3</sup>,  
Dr. Lavanya. A. Agrawal<sup>4</sup>

<sup>1</sup>(Department of Periodontology & implantology, Hitkarini Dental College, India)

<sup>2</sup>(Department of Orthodontics, C.D.C.R.I, India) <sup>3</sup>(Department of Orthodontics, New Horizon Dental College) <sup>4</sup>(Department of periodontology, New Horizon Dental College)

**Abstract:** Now a days Platelet-Rich Fibrin (PRF) is gaining more attention for obtaining periodontal regeneration. Platelet-rich fibrin (PRF) is considered a second-generation platelet concentrate that is widely used in osseous regeneration. The purpose of this case report is to present clinical and radiographic results of an intrabony periodontal defect treated with PRF. After surgical treatment with autologous PRF, six month follow up revealed a significant reduction in Pocket Probing Depth (PPD) and Relative Attachment Level (RAL) gain as well as radiographic bone formation, supporting the role of various growth factors present in the PRF in accelerating the soft and hard tissue healing. From the presented case, it can be concluded that PRF is clinically and radiographically efficacious in the treatment of a periodontal intrabony defect. Thus, signifying its role as a regenerative material in the treatment of intrabony defects.

**Keywords:** Platelet-Rich Fibrin; Intraosseous Defect; blood platelets; chronic periodontitis; regeneration.

### I. Introduction

The Periodontal diseases are among the most prevalent diseases worldwide. The ultimate goal of periodontal therapy includes not only the arrest of periodontal disease progression, but also the regeneration of structures lost due to disease. Periodontal regeneration can be defined as the complete restoration of lost tissues to their original architecture and function by recapitulating the crucial wound-healing events associated with their development<sup>1</sup>. Various biomaterials<sup>2-5</sup> based on endogenous regenerative technology (ERT), have been in used for periodontal tissue regeneration in addition to autogenous<sup>6,7</sup> and allogenic bone grafts<sup>8,9</sup>. Many platelet-rich plasmas (PRPs) obtained from cell separator units or from preparation rich in growth factors (PRGF) subfamilies do not contain leukocytes and were classified as pure PRP<sup>10,11</sup>. In contrast, PRPs containing leukocytes were classified as leukocyte rich PRPs. Products with a high-density fibrin network also exist and were classified as platelet-rich fibrin (PRF), some with leukocytes (leukocyte- and PRF) and some without leukocytes (pure PRF)<sup>10,11</sup>. Platelet rich fibrin (PRF) may be considered as a second generation platelet concentrate, because the natural concentrate is produced without any anticoagulants or gelifying agents<sup>12,13</sup>. PRF consists of an intimate assembly of cytokines, glycanic chains, and structural glycoproteins enmeshed within a slowly polymerized fibrin network. These biochemical components have well known synergetic effects on healing processes<sup>14</sup>. Beneficial effects of PRF have been studied in various procedures, such as facial plastic surgery<sup>15</sup>, a sinus-lift procedure as a sole osteoconductive filling material<sup>16</sup>, and multiple gingival recessions case treated with a coronally displaced flap<sup>17</sup>. Currently not a single graft material is considered as a gold standard in the treatment of intrabony defects. Considering that PRF may enhance the healing potential of bone and soft tissues. Here, we present a six month follow-up report of an intrabony defect, treated by means of an autologous PRF by assessing clinical and radiological parameters.

### II. Case Report

A 38-year-old female complaining of food lodgment and pain in the upper left maxillary molar region reported to Department of Periodontology and Implantology. Patient did not give any relevant medical history and there was no systemic condition that could interfere with physiological wound healing. There was no history of dental trauma or orthodontic treatment, and no injurious habit was reported by the patient. On intraoral examination, there was generalized bleeding on probing present but no swelling and no pus exudation was noticed. The probing pocket depth (PPD) on the distobuccal aspect of the tooth # 16 was 6 mm, relative attachment level (RAL) was 7 mm, whereas no mobility was detected in relation to 16 and fremitus was found to be negative. A periapical radiograph was taken using the paralleling cone techniques, which revealed presence of interproximal intrabony defects (IBD) with tooth #16. After recording all the findings, a thorough treatment plan was decided, initial therapy consisted of oral hygiene instructions, which were repeated until the patient achieved an O'Leary plaque score of 20% or below<sup>18</sup>. Scaling and root planing of the teeth were

## Treatment of a Intraosseous Defect with Platelet-rich fibrin (PRF) – A case report

performed. At 4 weeks following phase I therapy, a periodontal re-evaluation was performed to confirm the suitability of #16 tooth for this periodontal surgical procedure.

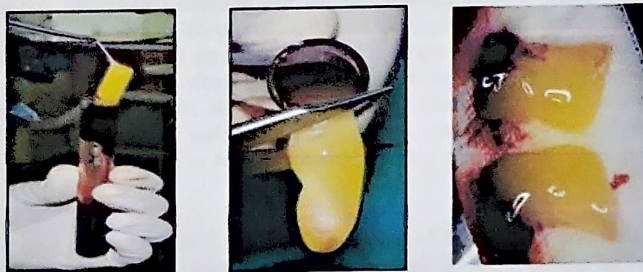### PRF Preparation:

The PRF was prepared in accordance with the protocol developed by Choukroun et al<sup>19</sup>. Intravenous blood (by venipuncturing of the antecubital vein) was collected in a 10-ml sterile tube without anticoagulant and immediately centrifuged in centrifugation machine at 3,000 revolutions (Approximately 400 g) per minute for 10 minutes. Blood centrifugation immediately after collection allows the composition of a structured fibrin clot in the middle of the tube, just between the red corpuscles at the bottom and acellular plasma (Platelet-poor plasma) at the top<sup>20</sup>. PRF was easily separated from red corpuscles base [preserving a small red blood cell (RBC) layer] using a sterile tweezers and scissors just after removal of Platelet-poor plasma (PPP) and then transferred onto a sterile dappen dish.



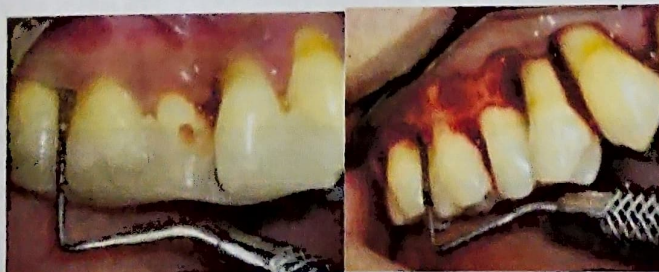WITHDRAWING OF PATIENT'S BLOOD      CENTRIFUGAL MACHINE AFTER CENTRIFUGATION

### PRF Handling



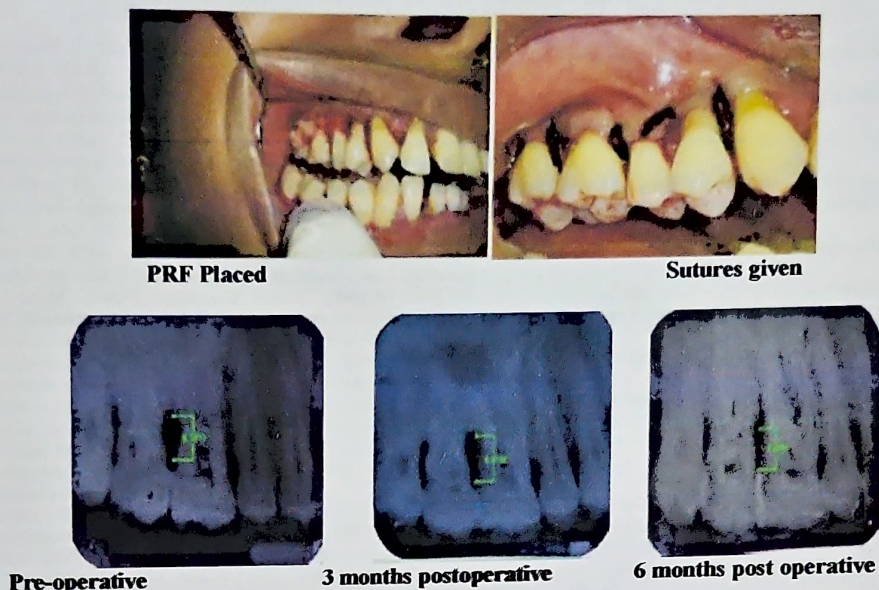
### Surgical Procedure:

Intra-oral antiseptics was performed with 0.2% chlorhexidine digluconate rinse and Iodine solution was used to carry out extraoral antiseptics. Following administration of local anesthesia, buccal and lingual sulcular incisions were made and mucoperiosteal flaps were reflected. Care was taken to preserve as much interproximal soft tissue as possible. Meticulous defect debridement and root planing were carried out using area specific curettes. No osseous recontouring was carried out. PRF of the required size was filled into the intrabony defect was used to cover the defect. The mucoperiosteal flaps were repositioned and secured in place using 3-0 non-absorbable black silk surgical suture. The simple interrupted sutures were placed. The surgical area was protected and covered with periodontal dressing.



Pre-operative

Intra-operative



#### **Postoperative Care:**

The Suitable antibiotics and analgesics (amoxicillin 500 mg four times per day for 5 days and ibuprofen 800 mg three times per day) were prescribed, along with chlorhexidine digluconate rinses (0.2%) twice daily for 2 weeks. Periodontal dressing and sutures were removed 2 weeks post-operatively. Surgical wounds were gently cleansed with 0.2% of chlorhexidine digluconate and patient was instructed for gentle brushing with a soft toothbrush. Patient was re-instructed for proper oral hygiene measures postoperatively and examined weekly up to 1 month after surgery and then 3 and 6 months. No subgingival instrumentation was attempted at any of these appointments. Re-examination at 6 months after the periodontal surgery revealed reduction in PPD (from 6 mm to 2 mm) and RAL (from 7 mm to 3 mm) with no sign of bleeding on probing and significant radiographic bone formation in the periodontal intrabony defect.

### **III. Discussion**

The present case report evaluated the clinical efficacy of PRF in the treatment of IBD. Reduction in PPD and gain in RAL are the major clinical outcomes measured to determine the success of any periodontal treatment. In the present case report, a significant reduction in PPD and RAL gain was found. The present case report also reflected the significant radiographic bone formation in the periodontal intrabony defect, supporting the role of various growth factors present in the PRF in accelerating the soft and hard tissue healing<sup>21</sup>. PRF by Choukran's technique is prepared naturally without addition of thrombin and it is hypothesized that PRF has a natural fibrin framework and can protect growth factors from proteolysis<sup>22</sup>. Thus, growth factors can keep their activity for a relatively longer period and stimulate tissue regeneration effectively. The main characteristics of PRF compared with other platelet concentrates, including platelet rich plasma (PRP), are that it does not require any anti-clotting agent<sup>20</sup>. The naturally forming PRF clot has a dense and complex 3-D architecture and this type of clot concentrates not only platelet but also leukocytes. Owing to its dense fibrin matrix, PRF takes longer to be resorbed by the host, which results in slower and sustained release of platelet and leukocyte derived growth factors in to the wound area<sup>14,23</sup>. PRF could improve the periodontal osseous defect healing, as PRF can up regulate phosphorylated extracellular signal regulated protein kinase expression and suppress the osteoclastogenesis by promoting secretion of osteoprotegerin (OPG) in osteoblasts cultures<sup>24</sup>. PRF also demonstrates to stimulate osteogenic differentiation of human dental pulp cells by upregulating OPG and alkaline phosphatase (ALP) expression<sup>25</sup>.

Furthermore, many growth factors are released from PRF as PDGF, TGF and have slower and sustained release up to 7 days<sup>16</sup> and up to 28 days<sup>26</sup>, which means PRF stimulates its environment for a significant time during remodeling. Moreover, PRF increase cell attachment, proliferation and collagen related protein expression of human osteoblasts<sup>27</sup>. PRF also enhances phosphorylated – extracellular signal regulated kinases, OPG and ALP expression which benefits periodontal regeneration by influencing human periodontal ligament fibroblasts<sup>28</sup>.

References

- [1] Polimeni G, Xiropaidis AV, Wikesjö UM. Biology and principles of periodontal wound healing/regeneration. *Periodontol* 2000;41:30-47.
- [2] Pradeep AR, Shetty SK, Garg G, Pai S. Clinical effectiveness of autologous platelet-rich plasma and Peptide-enhanced bone graft in the treatment of intrabony defects. *J Periodontol*. 2009;80:62-71.
- [3] Döri F, Kovacs V, Arweiler NB, et al. Effect of platelet rich plasma on the healing of intrabony defects treated with an anorganic bovine bone mineral: a pilot study. *J Periodontol*. 2009;80:1599-605.
- [4] Siciliano VI, Andreucci G, Siciliano AI, Blasi A, Sculean A, Salvi GE. Clinical outcomes after treatment of non-contained intrabony defects with enamel matrix derivative or guided tissue regeneration: a 12-month randomized controlled clinical trial. *J Periodontol*. 2011;82:62-71.
- [5] Wu SY, Chen YT, Chen CW, et al. Comparison of clinical outcomes following guided tissue regeneration treatment with a polylactic acid barrier or a collagen membrane. *Int J Periodontics Restorative Dent*. 2010;30:173-9.
- [6] Orsini M, Orsini G, Berilloch D, Aranda JJ, Sanz M. Long-term clinical results on the use of bone replacement grafts in the treatment of intrabony periodontal defects. Comparison of the use of autogenous bone graft plus calcium sulfate to autogenous bone graft covered with a bioabsorbable membrane. *J Periodontol*. 2008;79:1630.
- [7] Cochran DL, Jones A, Heijl L, Mellonig JT, Schoolfield J, King GN. Periodontal regeneration with a combination of enamel matrix proteins and autogenous bone grafting. *J Periodontol*. 2003;74:1269-8.
- [8] Nevins M, Hanratty J, Lynch SE. Clinical results using recombinant human platelet-derived growth factor and mineralized freeze-dried bone allograft in periodontal defects. *Int J Periodontics Restorative Dent*. 2007;27:421-427.
- [9] Hoidal MJ, Grimard BA, Mills MP, Schoolfield JD, Mellonig JT, Mealey BL. Clinical evaluation of demineralized freeze-dried bone allograft with and without enamel matrix derivative for the treatment of periodontal osseous defects in humans. *J Periodontol*. 2008;79:2273-80.
- [10] Dohan Ehrenfest DM, Bielecki T, Del Corso M, Inchingolo F, Sammartino G. Shedding light in the controversial terminology for platelet-rich products: Platelet-rich plasma (PRP), platelet-rich fibrin (PRF), platelet-leukocyte gel (PLG), preparation rich in growth factors (PRGF), classification and commercialism. *J Biomed Mater Res A* 2010;95:1280-1282.
- [11] Dohan Ehrenfest DM, Rasmusson L, Albrektsson T. Classification of platelet concentrates: From pure platelet-rich plasma (P-PRP) to leukocyte- and platelet-rich fibrin (L-PRF). *Trends Biotechnol* 2009;27:158-167.
- [12] Bowers GM, Chadroff B, Carnevale R, Mellonig J, Corio R, Emerson J. et al. Histologic evaluation of new attachment apparatus in humans. Part II. *J Periodontol*. 1989;60:676-682.
- [13] Cortellini P, Bowers GM. Periodontal regeneration of intrabony defects: an evidence-based treatment approach. *Int J Periodontics Restorative Dent*. 1995;15:128-145.
- [14] Dohan DM, Choukroun J, Diss A, et al. Platelet-rich fibrin (PRF): A second-generation platelet concentrate. Part II: Platelet-related biologic features. *Oral Surg Oral Med Oral Pathol Oral Radiol Endod* 2006;101:e45-e50.
- [15] Charrier JB, Montil JP, Albert S, Collon S, Bobin S, Dohan Ehrenfest DM. Relevance of Choukroun's platelet-rich fibrin (PRF) and SMAS flap in primary reconstruction after superficial or subtotal parotidectomy in patients with focal pleomorphic adenoma: A new technique. *Rev Laryngol Otol Rhinol (Bord)* 2008;129:313-318.
- [16] Mazor Z, Horowitz RA, Del Corso M, Prasad HS, Rohrer MD, Dohan Ehrenfest DM. Sinus floor augmentation with simultaneous implant placement using Choukroun's platelet-rich fibrin as the sole grafting material: A radiologic and histologic study at 6 months. *J Periodontol* 2009;80:2056-2064.
- [17] Aroca S, Keglévich T, Barbieri B, Gera I, Etienne D. Clinical evaluation of a modified coronally advanced flap alone or in combination with a platelet-rich fibrin membrane for the treatment of adjacent multiple gingival recessions: A 6-month study. *J Periodontol* 2009;80:244-252.
- [18] O'Leary TJ, Drake RB, Naylor JE. The plaque control record. *J Periodontol*. 1972;43:38.
- [19] Choukroun J, Adda F, Schoeffler C, Vervelle A. A 'opportunite' in parodontology: the PRF. *Implantodontie* 2001;42:55-62. (French)
- [20] Dohan DM, Choukroun J, Diss A, et al. Platelet-rich fibrin (PRF): A second-generation platelet concentrate. Part I: Technological concepts and evolution. *Oral Surg Oral Med Oral Pathol Oral Radiol Endod* 2006;101:e37-e44.
- [21] Dohan DM, Del Corso M, Charrier JB. Cytotoxicity analyses of Choukroun's PRF (Platelet Rich Fibrin) on a wide range of human cells: the answer to a commercial controversy. *Oral Surg Oral Med Oral Pathol Oral Radiol Endod*. 2007;103:587-93.
- [22] Lundquist R, Dziegiel MH, Agren MS. Bioactivity and stability of endogenous fibrogenic factors in platelet-rich fibrin. *Wound Repair Regen*. 2008;16:356-63.
- [23] Dohan DM, Choukroun J, Diss A, Dohan SL, Dohan AJ, Mouhyi J, et al. Platelet-rich fibrin (PRF): A second-generation platelet concentrate. Part III: Leukocyte activation: A new feature for platelet concentrates? *Oral Surg Oral Med Oral Pathol Oral Radiol Endod*. 2006;101:e51-5.
- [24] Chang IC, Tsai CH, Chang YC. Platelet-rich fibrin modulates the expression of extracellular signal-regulated protein kinase and osteoprotegerin in human osteoblasts. *J Biomed Mater Res A*. 2010;95:327-32.
- [25] Huang FM, Yang SF, Zhao JH, Chang YC. Platelet-rich fibrin increases proliferation and differentiation of human dental pulp cells. *J Endod*. 2010;36:1628-32.
- [26] Tsai CH, Shen SY, Zhao JH, Chang YC. Platelet-rich fibrin modulates cell proliferation of human periodontally related cells in vitro. *J Dent Sci*. 2009;4:130e5.
- [27] Wu CL, Lee SS, Tsai CH, Lu KH, Zhao JH, Chang YC. Platelet-rich fibrin increases cell attachment, proliferation and collagen-related protein expression of human osteoblasts. *Aust Dent J*. 2012;57:207-12.
- [28] Chang YC, Zhao JH. Effects of platelet-rich fibrin on human periodontal ligament fibroblasts and application for periodontal intrabony defects. *Aust Dent J*. 2011;56:365-71.
- [29] M Ozaki, Y. Adachi, Y. Iwahori, and N. Ishii, Application of fuzzy theory to writer recognition of Chinese characters, *International Journal of Modelling and Simulation*, 18(2), 1998, 112-116. (8).